Total Robotic Transabdominal & Transanal Total Mesorectal Excision – a video vignette

T.S. Suhardja[1], P.J. Smart[1], A.G. Heriot[1,2], S.K. Warrier[1,2]
[1]Epworth Healthcare, Melbourne, Victoria, Australia
[2]Department of Cancer Surgery, Peter MacCallum Cancer Centre, Victoria, Australia.

BACKGROUND

Total Mesorectal Excision (TME) is recognised as the standard of care for the surgical management of rectal cancer [1,2]. Risk factors that adversely affect the rate of R0 resections includes a narrow pelvis, male patient, locally advanced mid and distal rectal cancer, and anteriorly placed rectal cancer [1-2]. Transanal TME (TaTME) provides an ideal approach for this particular patient population, especially for optimum identification of distal resection margin. Data in the literature has supported the use of TaTME, as an alternative to laparoscopic or open TME, achieving either similar or better oncological outcome [3,4].

Fig 1. Robotic Transanal TME setup

DISCUSSION

We presented a novel modification of the Da Vinci Xi robotic platform, to perform a single surgeon total robotic transabdominal TME and transanal TME. We demonstrated the feasibility of this novel approach and the expansion of the use of the Da Vinci Xi platform.

SURGICAL TECHNIQUE

Patient positioned in a Lloyd-Davies position and procedure commenced with the transanal approach first. A GelPOINT® path (Applied Medical, Rancho Santa Margarita, CA, USA) transanal access platform was used along with Lone Star retractor (Lone Star Medical Products Inc, Houston, Texas, USA). Routine purse-string suture applied with adequate distal resection margin. GelSeal cap prepared with a diamond orientation of ports inclusive of three 8mm robotic ports, with the camera arm placed anteriorly and a posteriorly placed 8mm AirSeal® port (ConMed cooperation, Milford, Connecticut, USA). The procedure commenced with rectal mucosa circumferential marking of dissection plane. Full-thickness rectotomy performed before establishing the TaTME plane posteriorly first, before proceeding laterally then anteriorly. Dissection continued superiorly towards the peritoneal reflection, positively identifying important landmarks anteriorly, including periprostatic tissue and the endopelvic fascia, maintaining a complete mesorectal envelope. Once the peritoneal cavity is breached circumferentially, then the dissection was continued through the transabdominal approach.

Conventional robotic anterior resection and transabdominal TME performed with mobilisation of splenic flexure to provide non-tension anastomosis. Our preference is to extract the specimen through a Pfannenstiel incision, especially for bulky mesorectum and tight anal sphincter, in order to prevent tractional injury [5]. A conventional TaTME end-to-end colorectal anastomosis performed with a Covidien haemorrhoidal stapler (DST Series TM Technology, Covidien, Dublin, Ireland), with a covering loop ileostomy through a right iliac fossa port site. The total operative time was 210 minutes – 50 minutes for transanal phase and 160 minutes for transabdominal phase.

Fig 3. Robotic Transabdominal TME setup

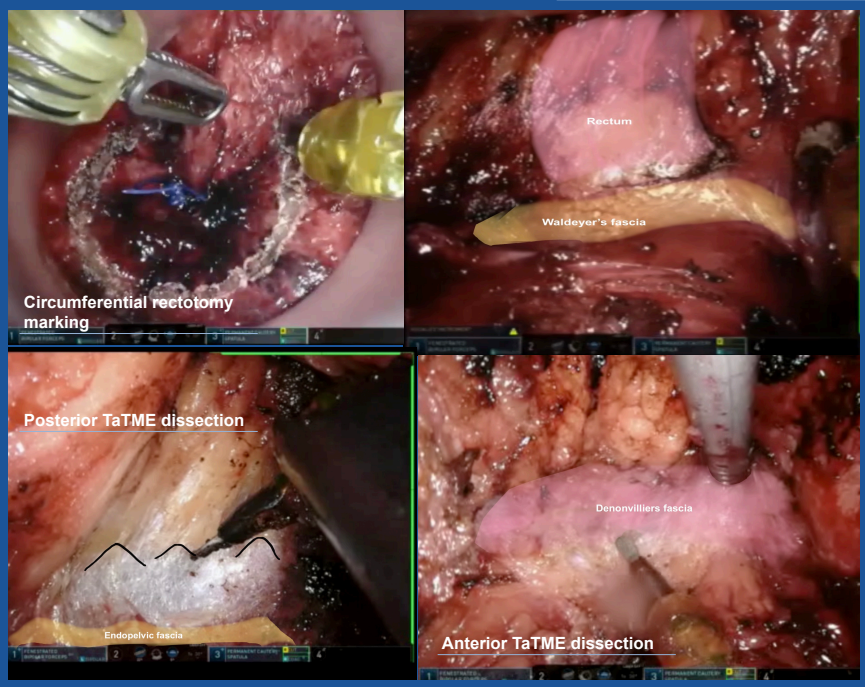

Fig 2. Transanal TME dissection

REFERENCES

1. Quirke P, Steele R, Monson J, et al. (2009), Effect of the plane of surgery achieved on local recurrence in patients with operable rectal cancer: a prospective study using data from the MRC CR07 and NCIC-CTG CO16 randomised clinical trial. *Lancet*, 373: 821–828.
2. Garlipp B, Ptok H, Schmidt U, et al. (2012), Factors influencing the quality of total mesorectal excision. *Br J Surg*, 99: 714–720.
3. Fernández-Hevia M, Delgado S, Castells A, et al. (2015), Transanal total mesorectal excision in rectal cancer: short-term outcomes in comparison with laparoscopic surgery. *Ann Surg.*, 261: 221–227.
4. Simillis C, Hompes R, Penna M, Rasheed S, Tekkis PP. (2016), A systematic review of transanal total mesorectal excision: is this the future of rectal cancer surgery? *Colorectal Disease*, 18: 19–36.
5. Lee SW, Ross HM, Rivadeneira DE, Steele SR, Feingold DL. (2017) Advanced Colonoscopy and Endoluminal Surgery. Springer International Publishing, New York, US.